Reprinted from Current Diagnosis 2
Edited by Howard F. Conn, M.D. and Rex B. Conn, Jr., M.D.
Published by W. B. Saunders Company, 1968

CHRONIC PULMONARY EMPHYSEMA*

By EARLE B. WEISS, M.D., SANFORD CHODOSH, M.D., and MAURICE S. SEGAL, M.D.
Tufts University School of Medicine, Boston, Massachusetts

Chronic pulmonary emphysema may be defined by many standards but at present is demonstrable directly by morphologic examination. Clinically, the major complaint is dyspnea, and this must be associated with increased expiratory airway resistance and hyperinflation of the lungs with actual destruction of alveolar wall structure.

Pathologically, emphysema is a disease affecting the acinus (basic respiratory unit, including respiratory bronchioles and alveoli) with the destruction of alveoli forming abnormally large air spaces, and resulting in a decrease in the amount of elastic tissue, and in the number and size of the capillary bed. The distribution of such alveolar destruction may be (a) centrilobular (centriacinar) or central acinar destruction, (b) panlobular (panacinar) or generalized acinar disease, and (c) paraseptal involving alveoli at the periphery of the acinus. Centrilobular emphysema appears to play a lesser role than panacinar emphysema, which is of more serious consequence. The latter affects lung bases and apices with equal severity. For radiological findings to be established, a grade III pathologic severity is usually present. Patients with chronic bronchitis, in which the x-ray film shows widespread emphysema, are subject to a 50 per cent mortality within 5 years. Interstitial emphysema and the focal emphysema of coal workers have less clinical significance. Blebs and bullae (large, thin-walled cystic air spaces) may occur in any form of emphysema and are referred to as localized or generalized bullous emphysema.

The cause and pathogenesis of chronic pulmonary emphysema are not known. Chronic bronchitis, particularly that occurring with heavy cigaret smoking, appears to be associated with emphysema in susceptible individuals. Once the full clinical spectrum develops, it is often difficult to separate chronic bronchitis from emphysema, though the latter may be the dominant component. Radiological and pathological studies indicate that while smokers show more emphysema than nonsmokers (2.5 times), the lungs of some nonsmokers reveal significant degrees of emphysema. Certainly, emphysema is more common in white males over the age of 40, in whom a history of coughing or smoking is present. Experimental studies with foreign materials (phosgene, nitrogen dioxide, etc.), epidemiologic analyses of air pollution factors, familial emphysema, and antitrypsin globulin deficiency states suggest that many factors may be contributory. The present explanations for the development of emphysema include: (a) a consequence of chronic bronchial (bronchiolar) obstruction, with air trapping and alveolar rupture; (b) direct destruction of alveoli from chronic inflammation or vascular ischemia; (c) degenerative or immunologic changes in bronchi or alveoli.

Factors that intensify airways obstruction are important clinically. Thus exacerbations of infectious or allergic bronchitis, cigaret smoking, occupational or air pollution irritants, sinusitis, and mucoviscidosis may contribute to expiratory airways obstruction by hypersecre-

* These studies were supported in part by a grant from The Council for Tobacco Research—U.S.A.

tion of mucus, inflammatory exudates, bronchial edema, bronchospasm, and bronchial fibrosis, epithelial metaplasia and hyperplasia, or loss of ciliary action. Once emphysema is established further dynamic airways obstruction may occur, when high expiratory pressures are employed to expel air or by the collapse of bronchi held patent normally by supporting perialveolar structures. Associated cough may produce sudden increases in intrabronchial pressure, thereby intensifying alveolar damage. It is doubtful whether bronchial asthma per se leads to chronic pulmonary emphysema, though clinically an "asthmatic" component may coexist.

Clinical Criteria

The main complaint is dyspnea, intermittent or exertional at the outset because of the large functional reserve of the lung, and later continuously. Orthopnea is uncommon unless there is superimposed cardiac failure. Even before radiological findings are apparent, the patient will describe gradual limitation in physical activity. Many give a history of wheezing or coughing with or without significant sputum production with the chronic cough often preceding all other symptoms. Fatigue, anorexia, and weight loss are common. Progressive hypoxemia, and/or respiratory acidosis will cause asterixis and cerebral abnormalities manifested by confusion, agitation, or personality changes.

Physical Examination

Early in the disease, general health appears good and the physical findings may be subtle. Later, evidence of tissue wasting and tachypnea with pursed lip breathing and excessive work of breathing will be observed. With established disease, the rib interspaces are widened and the thorax is hyperinflated (barrel-chested) and fixed, moving as a unit in inspiration with striking use of accessory respiratory muscles. A dorsal kyphosis is often present. The diaphragms are low and relatively immobile. Percussion note is hyperresonant and breath sounds are distinct with a prolonged expiratory phase. The presence of rhonchi and wheezing will depend upon local factors, with posttussive rales occurring frequently. Examination of the heart may reveal an ill-defined cardiac border, distant cardiac tones (often heard best in the epigastrium), and in the presence of pulmonary hypertension and right verticular enlargement, a sternal lift, S_2P being greater than S_2A, prominent A wave, diastolic

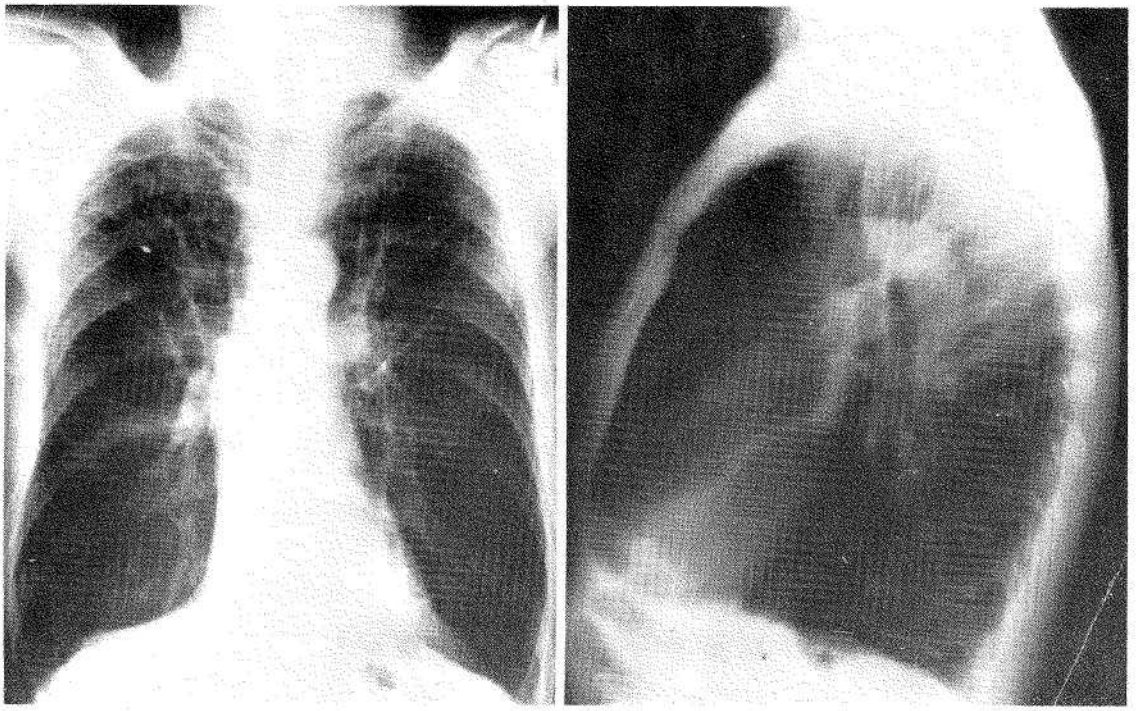

Figure 1. Posteroanterior lateral chest films in pulmonary emphysema. Apical fibrosis represents inactive tuberculosis (see text).

Figure 2. Tomogram showing large bullae in left lung and impaired vascular pattern.

gallop (RV), or tricuspid insufficiency murmur. The usual peripheral signs of congestive heart failure will be present in advanced stages associated with cor pulmonale. Clubbing, cyanosis, or edema may be noted. Profuse diaphoresis often accompanies states of decompensated respiratory acidosis.

Laboratory Study

Routine laboratory data are of limited value. Secondary polycythemia may be present with hypoxemia. The white blood cell count may rise during infection, however, often one sees only a shift to immature polymorphonuclear forms with a mild elevation in white count. Plasma chloride may fall and serum bicarbonate rise (> 25 mEq. per liter) with respiratory acidosis. The sputum may be mucoid at first, becoming purulent during infectious episodes. Sputum cytologic pattern is that seen in chronic bronchitis with polymorphonuclear cells, macrophages, bronchial epithelial cells, and background debris with pneumococci and *Hemophilus influenzae* in culture. (See section on chronic bronchitis.) The electrocardiogram demonstrates a pattern of right heart strain and systolic overload. The usual right axis deviation may be replaced by a left axis with overinflation and cardiac rotation.

Radiologic Criteria

Correlation between symptoms and radiologic findings is often poor in emphysema. Inspiratory and expiratory posteroanterior (*A*) and lateral (*B*) chest films are useful in determining air trapping and diaphragmatic movement (Fig. 1). A single midsagittal tomogram may define pulmonary vasculature patterns, while full tomography may delineate bullae (Fig. 2). Overpenetration producing fictitious loss of normal vascular markings is to be avoided. In diffuse emphysema, the following may be observed:

1. Hyperradiolucency of lung parenchyma and widened intercostal spaces.
2. Elongate, narrow vertical heart, and prominent pulmonary artery trunk (1.5 cm.) with accentuated hilar and tapered peripheral lung vessels (i.e. loss and distortion of the fine branching pattern of the vascular tree).
3. Low (seventh anterior interspace) and absolutely flat diaphragms.
4. Increased retrosternal (lateral) and retrocardiac air.
5. Bullae, which are avascular and of variable definition.

A mild degree of panlobular emphysema will not be seen radiologically and once the above criteria are observed, fairly extensive anatomic changes will be present.

Fluoroscopy may be employed to assess diaphragmatic motion, air trapping phenomenon, or gross patterns of regional ventilation.

Bronchography may reveal distortion by bullae, or the changes of chronic bronchitis (if present) with elongation, cutoffs, beading, and diverticula.

Physiology

The physiological findings will vary with the stage of disease, in particular the degree of airways obstruction, and the total amount of reduced ventilated lung volume, in relation to the effective pulmonary vascular perfusion. Recent bronchodynamic studies indicate that air flow limiting segments occur between segmental and mainstem bronchi.

Mechanics of Breathing. The slow or forced vital capacity may be normal, increased, or decreased, and thus of limited value alone. However, the forced expiratory volume will show reduction of first ($FEV_{1.0}$) and third second parameters (Fig. 3). The maximum voluntary ventilation (MVV) and expiratory flow rates (MMEFR, MEFR) are reduced.

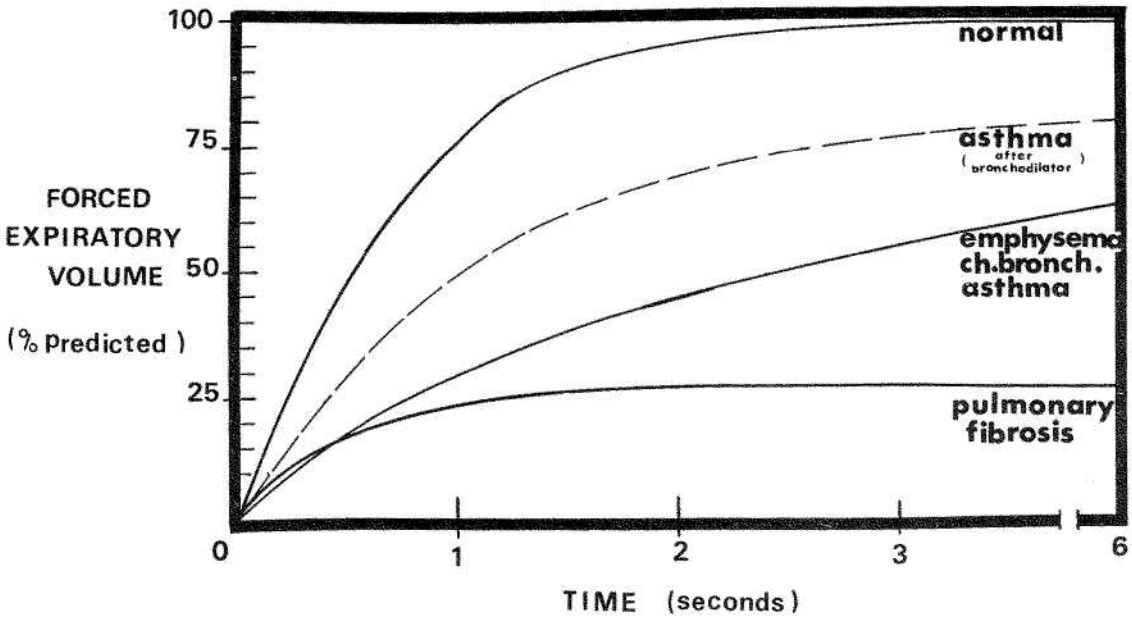

Figure 3. Schematic expiratory spirograms. In all conditions the forced expiratory volume is reduced compared to predicted values. In the airways obstructive syndromes, the percentage of first and third second ($FEV_{1.0}$, $FEV_{3.0}$) volumes (compared to the observed total FEV) are less than the normal of 75 per cent and 90 to 95 per cent predicted respectively. Some improvement is noted in asthma after use of bronchodilators. The percentage of $FEV_{1.0}$ and $FEV_{3.0}$ of the observed total FEV is normal in pulmonary fibrosis (restrictive pattern) even though the total FEV is reduced.

Dynamic lung compliance is usually reduced (static compliance may be increased), expiratory airway resistance is increased, and the work of breathing is elevated. Acute changes following use of bronchodilators are small or may indicate asthmatic or bronchitic components.

Lung Volume. The major finding is an increase in residual volume (or FRC) relative to the total lung volume.

Ventilation. Tidal volume, respiratory frequency, and minute ventilations may be normal or increased initially. Later in the course, this compensating mechanism will fail and the total ventilation will be decreased. Hyperventilation ($V_E/VO_2 > 35$) is often associated with a large oxygen cost of breathing. Physiologic dead space may be increased as the result of local imbalance in perfusion or the presence of bullae. Alveolar ventilation ($\dot{V}_A$) may be reduced, relative to total ventilation by the presence of increased dead space, and effective V_A should be compared with the arterial CO_2 tension for significance.

Distribution. Helium or nitrogen studies of inert gas distribution are abnormal, indicating that the gas movements are not equally distributed to the alveoli.

Gas Exchange. The A-a (alveolar–arterial) O_2 gradient is increased. Studies of the diffusing capacity of the lung for carbon monoxide ($DL_{CO}SS$) reveal a reduction in effective surface area. This may be due to ventilation/perfusion imbalance or direct changes in the pulmonary capillary bed.

Arterial Blood Gases and pH. Hypoxemia ($PO_2 < 85$ mm. Hg) with or without hypercapnemia ($PCO_2 > 45$ to 50 mm. Hg) and variable degrees of respiratory acidosis (pH < 7.35) depending upon renal and tissue buffering capacities, relate to severity of disease and the presence of complicating chronic bronchitis. In chronic respiratory acidosis for each 10 mm. rise in P_aCO_2 the "appropriate" rise in pH should be 3.2nM (H^+)/L indicating the absence of complicating metabolic disorders, such as metabolic alkalosis which is common as the result of diuretic therapy. Exercise may reduce P_aO_2. There is some evidence that pathologic microarteriovenous shunts will prevent a full response to 100 per cent O_2 breathing for 30 minutes.

Distinction from chronic bronchitis ("blue bloater" as contrasted with the "pink puffer" of emphysema) is not possible physiologically; however, the patient with chronic bronchitis

may show: (1) more rapid and shallow respiratory pattern; (2) reduced compliance; (3) greater dead space ventilation; (4) earlier development of hypoxemia and hypercapnia; (5) earlier development of cor pulmonale; (6) normal DLco.

Special Diagnostic Tests

Differential Bronchospirometry. May be of use in preoperative evaluation, particularly if unilateral lesion is present (viz., carcinoma, bullae).

Radioactive Isotopic Scan. Both perfusion and ventilation may be evaluated more completely by regional isotope scan studies, where technically available. Angiography may assess pulmonary vascular distribution.

Bronchoscopy. Findings during bronchoscopy are primarily those of bronchitis, if present. Bronchial collapse with expiration may be observed.

Complications

The nature of the pathologic process suggests that the physiological impairment in the disease is relatively fixed. However, acute intercurrent insults may precipitate ventilatory failure and CO_2 narcosis. Since this state is potentially reversible, their diagnosis becomes mandatory, e.g. exacerbation of infectious or allergic bronchitis, inspissation of secretions (sputum volume low, hard to raise and progressive dyspnea), bronchospasm, cor pulmonale, pneumonitis, pneumothorax, gastrointestinal bleeding, pulmonary thromboembolism, drug or O_2 depression of ventilation or pleural effusion. Inguinal hernia and peptic ulcer disease also occur as complications in emphysema.

Course

Interestingly, many patients manage to function for many years after emphysema is first documented. However, the general course for such patients is a variable but definite deterioration and limitation in physical function. There is a tendency to worsen during the winter months with frequent episodes of infectious bronchitis. Pulmonary hypertension and cor pulmonale (see section on cor pulmonale) usually occur late in the course, as the result of a decreased pulmonary capillary bed, plus functional and organic pulmonary vascular changes due to hypoxia, acidosis, and polycythemia. Alterations in blood gases, reduction in ventilatory ability, age of onset of disease, etc., are poor prognostic signs. However, clinical evidence indicates that careful supportive medical care and physical and inhalation therapy may help maintain the patient with less morbidity and greater productiveness.